

A Survey of Mammographic Image Processing Algorithms for Bilateral Asymmetry Detection

Jelena Bozek, Mario Mustra, Mislav Grgic

University of Zagreb, Faculty of Electrical Engineering and Computing

Department of Wireless Communication

Unska 3/XII, HR-10000 Zagreb, Croatia

E-mail: jelena.bozek@fer.hr

Abstract - Breast cancer is the most common cancer in women. Early detection and diagnosis of breast cancer facilitated with digital mammography can increase survival rate and chances for patient's complete recovery. Bilateral asymmetry is one the breast abnormalities that may indicate breast cancer in early stage of its development. Researchers have been investigating and developing image processing algorithms that may help radiologists in giving accurate diagnosis. Most detection algorithms indicate suspicious regions that may need a better observation. This paper presents a survey of algorithms that have been developed for bilateral asymmetry detection. An overview of algorithms for alignment of the left and right breast is given and methods for comparison of the left and right breast are presented.

Keywords - Bilateral Asymmetry, Breast Alignment, Digital Mammography, Computer-Aided Detection

1. INTRODUCTION

Breast cancer represents 10% of all cancers diagnosed worldwide annually and constituted 22% of all new cancers in women in 2000, making it by far the most common cancer in women [1]. Detection and diagnosis of breast cancer in early stages of development increases possibility of successful treatment and increases chances for complete recovery of the patient. For early breast cancer detection one of the best examination procedures is still mammography. Mammographic screening programs have reduced mortality rates by 30-70% [2]. In mammographic images early signs of breast cancer, such as bilateral asymmetry, can be revealed. Bilateral asymmetry is asymmetry of the breast parenchyma between corresponding regions in left and right breast. According to ACR's (American College of Radiology) Breast Imaging Reporting and Data System [3] there are two types of bilateral asymmetry: global asymmetry and focal asymmetry. Global asymmetry is defined when a greater volume of fibroglandular tissue is present in one breast compared to the corresponding area in the other breast and focal asymmetry is circumscribed area of asymmetry seen on two views, but it lacks the borders and conspicuity of a mass. Focal asymmetry is usually an island of healthy fibroglandular tissue that is superimposed with surrounding fatty tissue. Asymmetric breast tissue can be expected in approximately 3% of the population [4]. Asymmetric breast tissue is usually benign, but an asymmetric area may indicate a

developing mass or an underlying cancer [5]. Thus, asymmetrical breasts could be reliable indicators of future breast disease in women and this factor should be considered in a woman's risk profile [6]. Asymmetries of concern are those that are changing or enlarging or are new, those that are palpable and those that are associated with other findings, such as microcalcifications or architectural distortion [7].

Radiologist compares left and right mammographic images searching for visual cues that may indicate presence of breast lesion. Radiologist's misinterpretation of the lesion can lead to a greater number of false positive cases. 65-90% of the biopsies of suspected cancers turn out to be benign [8]. Thus, it is important to develop a system that could aid in the decision between follow-up and biopsy. Objective and quantitative analysis facilitated by the application of computers to biomedical image analysis leads to a more accurate diagnostic decision by the physician [9]. Computer-aided detection (CAD) systems have been developed to improve the results of mammographic screening programs by assisting radiologists in decision between follow up and biopsy, thereby decreasing the number of false positive cases.

This paper presents a survey of image processing algorithms developed for detection of bilateral asymmetry in mammography. Section 2 presents methods developed for registration and alignment of left and right breast. Section 3 presents some developed algorithms and methods proposed for bilateral asymmetry detection. Section 4 draws the conclusion and gives some final remarks.

2. REGISTRATION OF PAIRS OF MAMMOGRAPHIC IMAGES

Some researchers in their work performed some kind of alignment or registration of the right and left breast as a first step in bilateral asymmetry detection algorithms [10-16]. Other researchers proposed methods where registration is not necessary [17-21]. Most of the algorithms for mammographic image registration are developed for use in temporal analysis of mammographic images [22-25], but some main principles and ideas may be applied in alignment and registration of left and right mammographic images. The medical image registration techniques may be divided into two groups [26]: techniques that use features such as curves and points to match the images and techniques that use image gray level values. Another categorization of image registration methods may be divided into rigid and nonrigid techniques. Rigid registration techniques align images using rotation and translation while nonrigid techniques assume a nonlinear transformation model and can adjust image for warping [27]. Breast registration and alignment procedures have to confront many difficult problems such as the natural asymmetry of the breasts, absence of good corresponding points between left and right breast images to perform matching and distortions inherent to breast imaging [20]. Alignment ensures that the correct corresponding points of the left and right breast are being compared. An example of left and right craniocaudal (CC) and mediolateral oblique (MLO) images that are not aligned is shown in Fig. 1.

Most researchers use some breast landmarks as control points to match the breasts and compare the corresponding regions. Lau and Bischof [10] aligned breast areas using three control points on the boundary for guiding the alignment process. These control points were the nipple point and two corner points between the breast boundary and the chest wall, as depicted in Fig. 2. The alignment of the left and right breast areas was achieved in four steps: rotation of one mammographic image to match the breast orientations, alignment of both images to the point C_m , transformation of one image to obtain $\Theta_L = \Theta_R$ and compensation for possible differences in size and shape.

Yin et al. [11] extracted breast border and nipple position as landmarks for the alignment of left and right breast. They identified breast border by a four point connectivity tracker and nipple position was identified based on the presence of a thicker skin line and greater subcutaneous parenchymal opacity around the nipple position. Image registration was accomplished in two steps: determining a constrained correspondence between locations along the borders of the two breasts and matching the established corresponding points of the right breast image with those of the left breast image using the

least-square methods that involved translation and rotation.

Méndez et al. [12] also used nipple and breast border as a reference point for the alignment of the breasts. The coordinates of the detected nipples of both images determined the displacement and the coordinates of the points along the detected breast borders were used to determine the angle of rotation to achieve correspondence. The left breast image was rotated according to the angle of rotation so that the left breast border matched the right breast border.

Stamatakis et al. [13] aligned left and right breast using a single reference, a point of maximum curvature on the breast curve. They normalized the images to minimize differences in illumination between images before comparison.

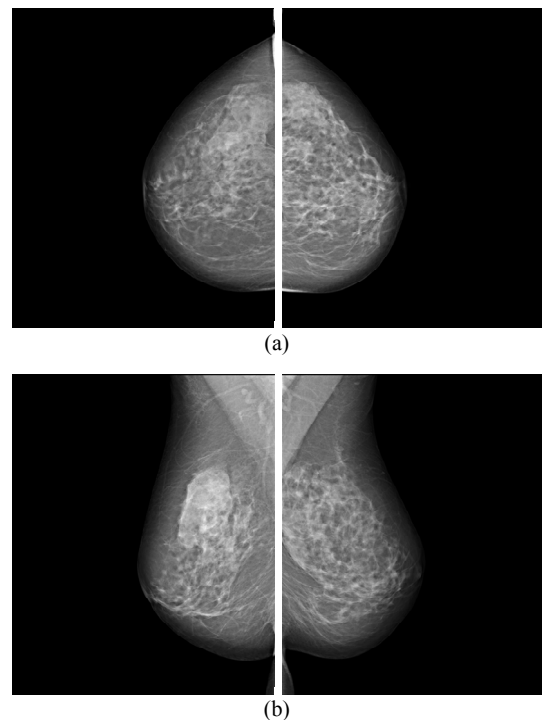


Fig. 1. Left and right breasts in (a) CC and (b) MLO views.

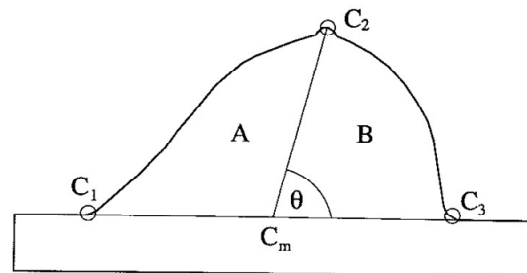


Fig. 2. Schematic outline of breast area with three control points. [10]

Wirth et al. [14] proposed a method which accounts for some of the nonrigid-body characteristics associated with breasts. They selected corresponding control points between left and right mammographic image from the breast contour and according to these control points they applied a multiquadric radial basis function (RBF) to transform right mammographic image to match relative the left mammographic image.

Good et al. [16] applied techniques for automatically making the appropriate local image corrections, based on the variations in tissue thickness during breast compression. Afterwards they used a nonlinear geometrical transformation which geometrically deformed the images to match a semicircular template as it is shown in Fig. 3.

Georgsson [15] proposed method for bilateral registration based on anatomical features and assumptions of how the female breast is deformed under compression. He established an anatomical coordinate system defined with pectoral muscle and nipple. The coordinate system was used to divide breast into two boxes containing upper and lower part of the breast as depicted in Fig. 4. He independently scaled each of these boxes to match the bilateral counterpart in size and transformed the skin lines of the two breasts to match each other.

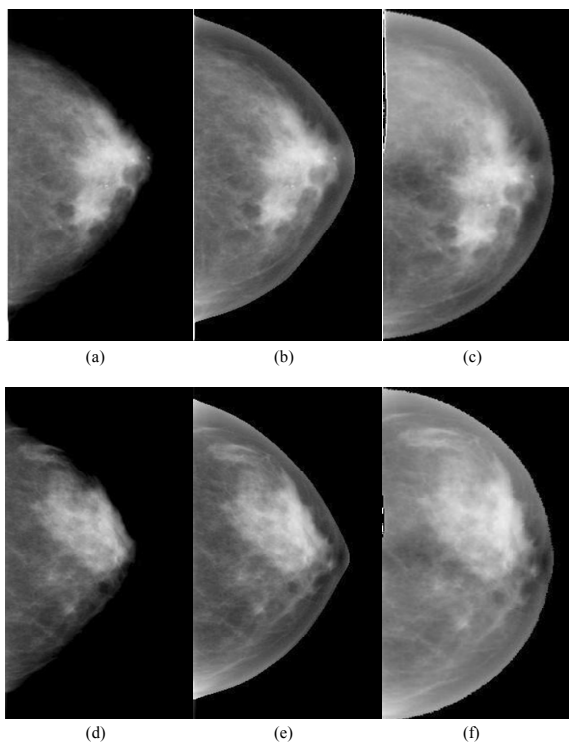


Fig. 3. CC views of the left and right breasts of a woman having a malignant mass in the left breast. Original images are shown in (a) and (d). Thickness-corrected and geometrically transformed versions are shown in (b) and (e) and in (c) and (f), respectively. [16]

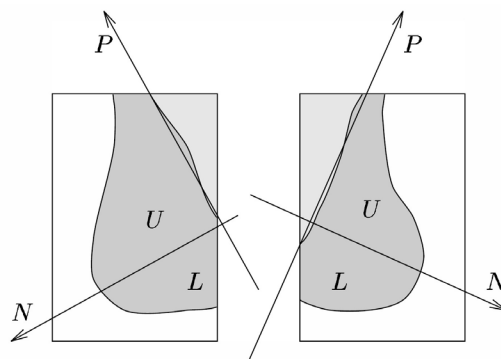


Fig. 4. Coordinate system for breast alignment. [15]

3. BILATERAL ASYMMETRY DETECTION ALGORITHMS

Lau and Bischof [10] used detection of structural asymmetries between corresponding regions in the left and right breast to detect breast tumors. They used a set of measures related to the mammographic appearance of tumors but without characteristics of specific tumors. They developed measures of brightness, roughness, brightness-to-roughness and directionality. The method was evaluated using set of 10 pairs of mammographic images where structural asymmetry was a significant factor in the radiologist's diagnosis. These mammographic images contained a total of 13 suspicious areas. Final test results revealed sensitivity of 92% with 4.9 false positives per pair of mammographic images.

Méndez et al. [12] subtracted left and right mammographic images and applied a threshold to obtain a binary image with the information of suspicious areas. The suspicious regions or asymmetries were delimited by a region growing algorithm. The method was tested on a set of 70 pairs of digital mammographic images and obtained a true positive rate of 71% with 0.67 false positives per image.

Stamatakis et al. [13] proposed two methods for the comparison of left and right breast. The first method, Single Image Comparison (SIC), involved finding the corresponding areas whose intensities differed more than a preset threshold. The second method, Multiple Image Comparison (MIC), involved generating eight pairs of images from each original pair of left and right images. These eight pairs of images were then bilaterally compared and the resulting images were recombined into one pair of images. A set of 10 features was calculated from the suspicious areas detected by the comparison process. Stepwise discriminant analysis was used to select 5 features for final feature set. The results were tested on a data set of 50 pairs of mammographic images. The SIC method obtained 86.8% accuracy with 4.9 false positives per image and MIC method obtained 89.2% accuracy with 4.3 false positives per image.

Georgsson [15] proposed two methods for differential analysis of bilateral mammographic images. The first method was based on the absolute difference between the registered images and the second method was based on the statistical differences between properties of corresponding neighborhoods. He tested both methods on 100 mammographic images obtained from the MIAS database. The absolute difference method achieved a detection rate of 18 with 10 false positives and statistical method achieved detection rate of 21 with 10 false positives.

Good et al. [16] developed a method which performs feature-based analysis of local and global differences between mammographic images. The extracted features are assumed to be relatively invariant with respect to breast compression. After the registration of the images with template, they applied a series of global and local feature filters to characterize the image properties of interest. Features are placed into feature vector and appropriate comparison of feature vectors reveals differences between image properties.

Miller and Astley [17] used anatomical features for detection of breast asymmetry. Using texture analysis they segmented mammographic images into regions of fat and nonfat tissue which presents glandular disc. Glandular discs in left and right breast were compared using properties of their shape and grey-level distribution. They tested the proposed method on a data set of 30 pairs of mammographic images and achieved classification accuracy of 86.7% with false positive rate of 16.7%. In another work, Miller and Astley [18] compared glandular discs in left and right breast using shape, brightness and topology features. Measurements of shape were used to detect architectural distortion of the glandular disc, brightness distribution was used to detect masses and focal densities and topological features specified other suspicious asymmetries. The method was tested on the data set of 104 pairs of mammographic images and obtained classification accuracy of 74%.

Tahmoush and Samet [19] proposed the use of image similarity to determine asymmetry. They filtered the mammographic images to find the contextually similar suspicious points that could be malignant. Their similarity or asymmetry analysis used comparison of the values of the sets of suspicious points using modeling and supervised learning of model parameters. They used Bayes' Theorem to incorporate asymmetry into CAD system. Their method correctly classified 84% of images in their test set. The method correctly classified 97% of cancerous cases and 42% of non-cancerous cases.

Ferrari et al. [20] developed a method for the asymmetry analysis based on the detection of linear directional components using a multiresolution

representation based on Gabor wavelets. They segmented the fibroglandular disc and decomposed the resulting image using a bank of Gabor filters. The Gabor filter responses for different scales and orientation were analyzed using Karhunen-Loève (KL) transform and Otsu's thresholding method. For quantitative and qualitative analysis of the oriented patterns the rose diagrams were used. Their method obtained classification accuracy of up to 74.4%.

Rangayyan et al. [21] extended the method of Ferrari et al. [20] by including morphological measures and geometric moments of the fibroglandular disc related to density distributions. Directional features were obtained from the difference in rose diagrams and additional set of features including Hu's moments, eccentricity, stretch, area and average density were extracted from the segmented fibroglandular discs. They aligned the directional data related to the rose diagrams with respect to the corresponding pectoral muscle edges as shown in Fig. 5. The differences between the pairs of the features for the left and right mammographic image were used as measures for the analysis of asymmetry. They obtained the overall classification accuracy of 84.4%.

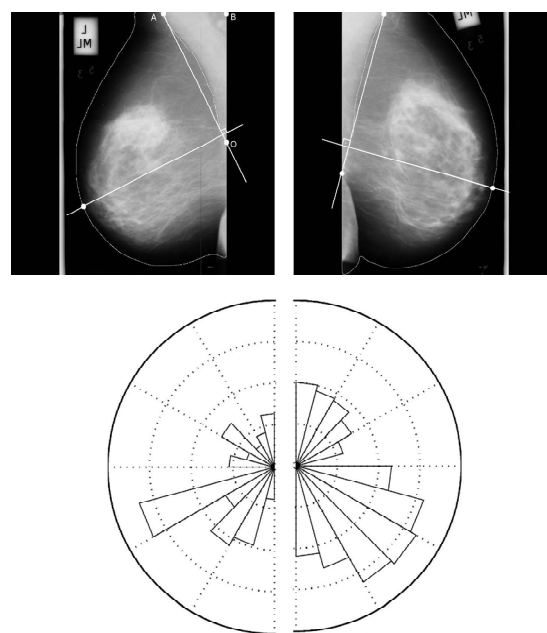


Fig. 5. Original MLO images and rose diagrams after alignment of directional data. [21]

Table 1 presents a summary of different approaches for bilateral asymmetry detection and their performance. Although several methods demonstrated very good classification accuracy above 85% there is still need for improvement of bilateral asymmetry detection algorithms and development of detection algorithms with lower false positive rates.

Table 1. Summary of methods for bilateral asymmetry detection and their performance. *

Authors	Description	Summary of results
Lau and Bischof [10]	Detection of structural asymmetries	Sensitivity of 92% with 4.9 false positives per pair of mammographic images
Méndez et al. [12]	Subtraction of images, obtaining suspicious area and delimiting them by a region growing algorithm	True positive rate of 71% with 0.67 false positives per image
Stamatakis et al. [13]	Single Image Comparison (SIC) and Multiple Image Comparison (MIC)	SIC method achieved 86.8% accuracy with 4.9 false positives per image and MIC method achieved 89.2% accuracy with 4.3 false positives per image
Georgsson [15]	Absolute difference method and statistical method	Absolute difference method achieved a detection rate of 18 with 10 false positives and statistical method achieved detection rate of 21 with 10 false positives
Miller and Astley [17]	Use of anatomical features - shape and grey-level distribution of glandular discs	Classification accuracy of 86.7% with false positive rate of 16.7%
Miller and Astley [18]	Use of shape, brightness and topology features of glandular discs	Classification accuracy of 74%
Tahmoush and Samet [19]	Use of image similarity	Correct classification of 84% of the mammographic images, 97% of cancerous cases and 42% of non-cancerous cases
Ferrari et al. [20]	Directional filtering with Gabor wavelets	Classification accuracy of up to 74.4%
Rangayyan et al. [21]	Directional features, morphological measures and geometric moments of the fibroglandular disc related to density distributions	Overall classification accuracy of 84.4%

* Only research with ROC analysis and/or pattern classification results is listed.

4. CONCLUSION

Mammography is one of the best examination procedures for early detection of breast cancer. It can reveal breast abnormalities in early stage of development. Due to wide range of breast abnormality features and large amount of mammographic images in screening programs, use of computers in breast cancer detection can help radiologists in giving more accurate diagnosis. Bilateral asymmetry may indicate breast cancer in its early stage. There have been developed image processing algorithms for bilateral asymmetry detection, but further developments are required to improve these algorithms and their performance.

ACKNOWLEDGEMENT

The work in this paper was conducted under the research project "Intelligent Image Features Extraction in Knowledge Discovery Systems" (036-0982560-1643), supported by the Ministry of Science, Education and Sports of the Republic of Croatia.

REFERENCES

- [1] O.M.N. Khatib, A. Modjtabai, *Guidelines for the early detection and screening of breast cancer*, EMRO Technical Publications Series 30, WHO, Cairo, 2006, 11 pages, available at: www.emro.who.int/publications/Book_Details.asp?ID=530
- [2] R.M. Rangayyan, F.J. Ayres, J.E.L. Desautels, "A Review of Computer-Aided Diagnosis of Breast Cancer: Toward the Detection of Subtle Signs", *Journal of the Franklin Institute*, Vol. 344, No. 3-4, 2007, pp. 312-348
- [3] American College of Radiology (ACR): *ACR Breast Imaging Reporting and Data System, Breast Imaging Atlas*, 4th Edition, Reston, VA, USA, 2003
- [4] D.B. Kopans, C.A. Swann, G. White, K.A. McCarthy, D.A. Hall, S.J. Belmonte, W. Gallagher, "Asymmetric breast tissue", *Radiology*, Vol. 171, No. 3, June 1989, pp. 639-643
- [5] P. Samardar, E.S. de Paredes, M.M. Grimes, J.D. Wilson, "Focal Asymmetric Densities Seen at Mammography: US and Pathologic Correlation", *Radiographics*, Vol. 22, 2002, pp. 19-33

- [6] D. Scutt, G.A. Lancaster, J.T. Manning, "Breast asymmetry and predisposition to breast cancer", *Breast Cancer Research*, Vol. 8, March 2006, R 14, available at: breast-cancer-research.com/content/8/2/R14S
- [7] E.S. de Paredes, *Atlas of Mammography*, 3rd Edition, Lippincott Williams & Wilkins, Philadelphia, USA, 2007
- [8] H.D. Cheng, X.J. Shi, R. Min, L.M. Hu, X.P. Cai, H.N. Du, "Approaches for Automated Detection and Classification of Masses in Mammograms", *Pattern Recognition*, Vol. 39, Issue 4, 2006, pp. 646-668
- [9] R.M. Rangayyan, *Biomedical Image Analysis*, CRC Press LLC, Boca Raton, FL, USA, 2005
- [10] T.-K. Lau, W.F. Bischof, "Automated Detection of Breast Tumors Using the Asymmetry Approach", *Computers and Biomedical Research*, Vol. 24, No. 3, 1991, pp. 273-295
- [11] F.-F. Yin, M.L. Giger, K. Doi, C.J. Vyborny, R.A. Schmidt, "Computerized Detection of Masses in Digital Mammograms: Automated Alignment of Breast Images and its Affect on Bilateral-Subtraction Technique", *Medical Physics*, Vol. 21, No. 3, March 1994, pp. 445-452
- [12] A.J. Méndez, P.G. Tahoces, M.J. Lado, M. Souto, J.J. Vidal, "Computer-Aided Diagnosis: Automatic Detection of Malignant Masses in Digitized Mammograms", *Medical Physics*, Vol. 25, No. 6, June 1998, pp. 957-964
- [13] E.A. Stamatakis, I.W. Ricketts, A.Y. Cairns, T. Walker, P.E. Preece, "Detecting Abnormalities on Mammograms by Bilateral Comparison", *IEE Colloquium on Digital Mammography*, London, UK, March 1996, pp. 12/1-12/4
- [14] M.A. Wirth, C. Choi, A. Jennings, "A Nonrigid-Body Approach to Matching Mammograms", *Seventh International Conference on Image Processing and Its Applications*, Manchester, UK, July 1999, pp. 484-488
- [15] F. Georgsson, "Differential analysis of bilateral mammograms", *International Journal on Pattern Recognition and Artificial Intelligence*, Vol. 17, July 2003, pp. 1207-1226
- [16] W.F. Good, X.H. Wang, G. Maitz, "Feature-based Differences Between Mammograms", *Medical Imaging 2003: Image Processing, Proceedings of SPIE*, Vol. 5032, 2003, pp. 919-929
- [17] P. Miller, S. Astley, "Detection of Breast Asymmetry Using Anatomical Features", in: R.S. Acharya, C.B. Goldgof (Eds.), *Biomedical Image Processing and Biomedical Visualization, Proceedings of SPIE*, Vol. 1905, 1993, pp. 433-442
- [18] P. Miller, S. Astley, "Automated detection of breast asymmetry using anatomical features", in: K.W. Bowyer, S. Astley (Eds.), *State of the Art in Digital Mammographic Image Analysis, Series in Machine Perception and Artificial Intelligence*, Vol. 9, World Scientific, River Edge, NJ, 1994, pp. 247-261
- [19] D. Tahmouh, H. Samet, "Image Similarity and Asymmetry to Improve Computer-Aided Detection of Breast Cancer", *Proceedings of the International Workshop on Digital Mammography (IWDM) 2006*, pages 221- 228, Manchester, UK, June 2006.
- [20] R.J. Ferrari, R.M. Rangayyan, J.E.L. Desautels, A.F. Frere, "Analysis of Asymmetry in Mammograms via Directional Filtering with Gabor Wavelets", *IEEE Transactions on Medical Imaging*, Vol. 20, No. 9, September 2001, pp. 953-964
- [21] R.M. Rangayyan, R.J. Ferrari, A.F. Frere, "Analysis of Bilateral Asymmetry in Mammograms Using Directional, Morphological, and Density Features", *Journal of Electronic Imaging*, Vol. 16, No. 1, January-March 2007
- [22] N. Vujovic, D. Brzakovic, "Establishing the Correspondence Between Control Points in Pairs of Mammographic Images", *IEEE Transactions on Image Processing*, Vol. 6, No. 10, October 1997, pp. 1388-1399
- [23] K. Marias, C. Behrenbruch, S. Parbhoo, A. Seifalian, Michael Brady, "A Registration Framework for the Comparison of Mammogram Sequences", *IEEE Transactions on Medical Imaging*, Vol. 24, No. 6, June 2005, pp. 782-790
- [24] S. Timp, N. Karssemeijer, "Interval Change Analysis to Improve Computer Aided Detection in Mammography", *Medical Image Analysis*, Vol. 10, No. 1, February 2006, pp. 82-95
- [25] F.J.P. Richard, P.R. Bakic, A.D.A. Maidment, "Mammogram Registration: A Phantom-Based Evaluation of Compressed Breast Thickness Variation Effects", *IEEE Transactions on Medical Imaging*, Vol. 25, No. 2, February 2006, pp. 188-197
- [26] F.J.P. Richard, L.D. Cohen, "A New Image Registration Technique with Free Boundary Constraints: Application to Mammography", *Computer Vision and Image Understanding*, Vol. 89, 2003, pp. 166-196
- [27] P. Kotsas, "Rigid Registration of Medical Images Using Binary Projections", available at: www.kotsas.gr/downloads/technicalreport.pdf